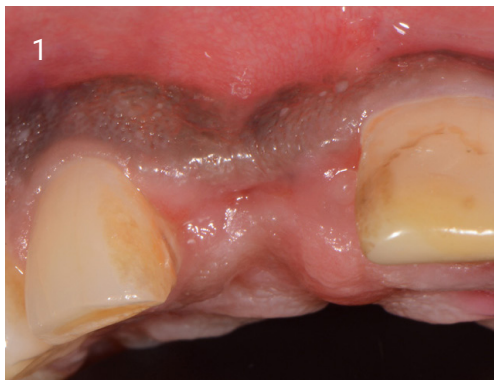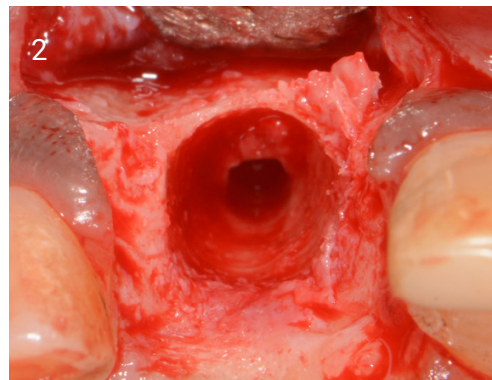


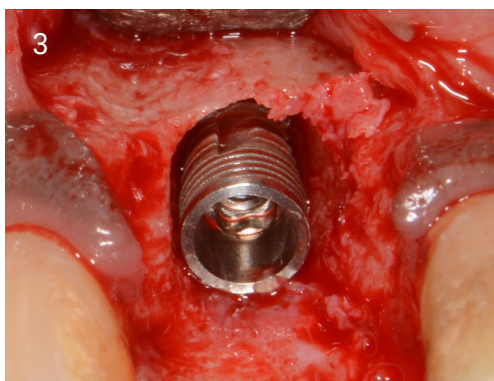
## ANTERIOR RIDGE CASE STUDY



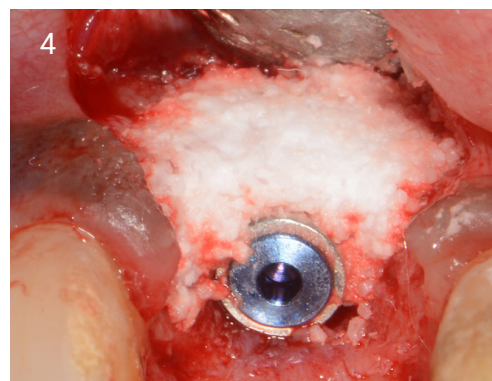
1. Case at 4 weeks post extraction, profile loss.



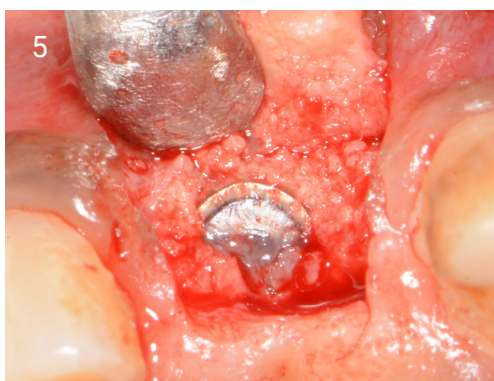2. Bone loss and site cleaned showing pilot drill site.



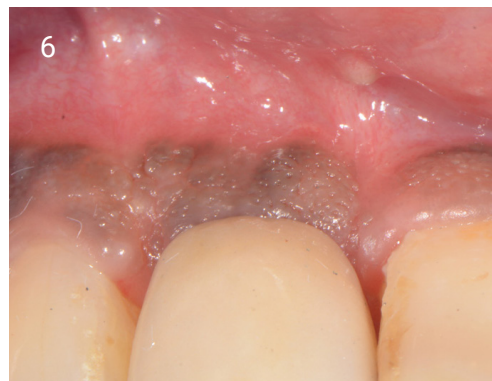3. Placement of implant to the correct level.



4. Grafted with EthOss®.



5. New bone at 12 weeks.



6. Restored 3 months.