

# Implant and alloplast synergy in a complex anterior maxillary case

Mark Worthing BDS (Wales), FDS RCS (Eng.), UK

The labial portion of the anterior maxilla provides unique challenges for intra-oral host bone regeneration. The aesthetic zone presents minimal margin for error. This case study demonstrates the use of novel implant design together with  $\beta$ -tricalcium phosphate ( $\beta$ -TCP) particulate alloplast graft material in the anterior maxilla for immediate tooth replacement therapy.

## Introduction

A 27-year-old female patient, non-smoker, with a non-contributory medical history presented with a painful upper left lateral incisor-tooth 22. The symptomatic tooth had been orthograde root treated twice with a subsequent apicectomy

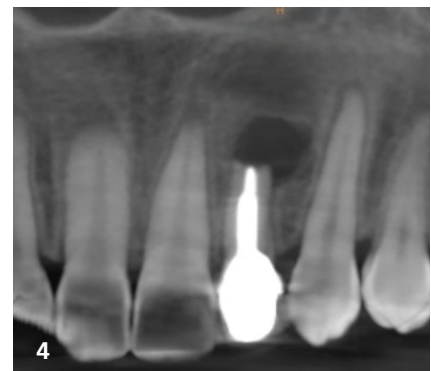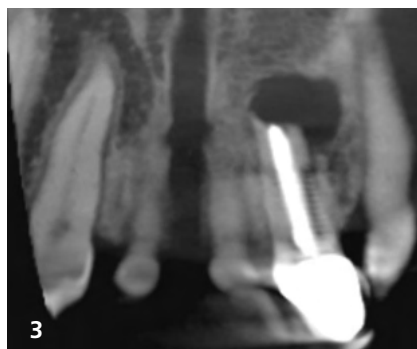
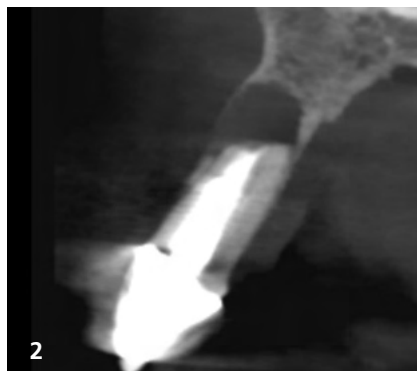
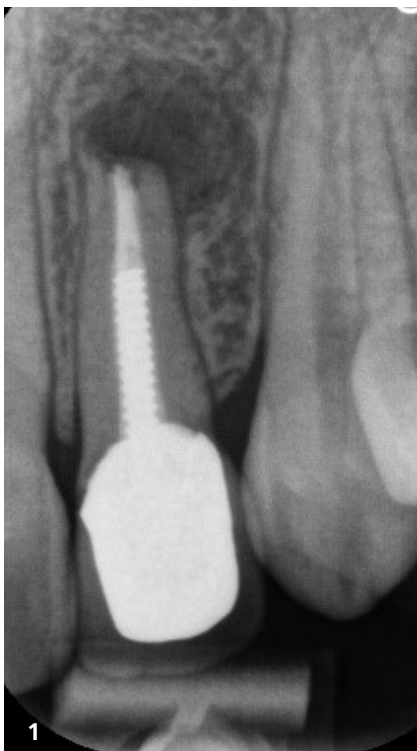
with no apparent retrograde filling material. At presentation (Figs. 1–4), the tooth was tender to vertical percussion, with no excess mobility. No increased probing depth or suppuration was noted, either on the affected tooth or elsewhere in the mouth. Marginal gingivitis was noted, localised to tooth 22. A diagnosis of chronic apical periodontitis secondary to suboptimal orthograde root treatment was made for tooth 22 and the tooth was given a hopeless prognosis.

## Surgical procedure

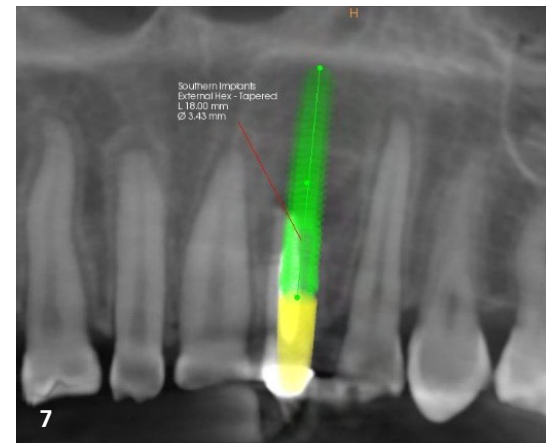
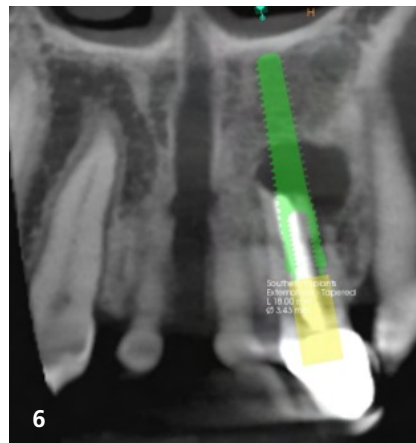
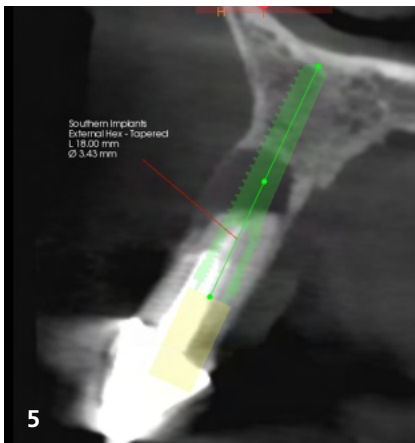
An immediate tooth replacement therapy implant treatment plan was proposed (Figs. 5–7). The initial treatment plan involved the fabrication of a com-

posite shell provisional crown, designed based on the preoperative diagnostic wax up optimised for immediate loading; a pre-extraction, small field, sectional CBCT scan on the anterior maxilla; a minimally traumatic extraction of tooth 22 with meticulous degranulation and sharp curettage; and an immediate implant placement using a novel implant with internal angle correction and a machined coronal surface texture.

A simultaneous bone grafting with an *in situ* hardening synthetic resorbable bone substitute was then used, composed of  $\beta$ -TCP and calcium sulphate (CS), according to Fairbairn and Leventis<sup>1-4</sup> and simultaneous loading of the implant with a composite provisional crown which is modified at chairside.



**Fig. 1:** Periapical radiograph showing failed orthograde root canal treatment with apical radiolucency. **Fig. 2:** CBCT section showing the extent of the radiolucency and the residual bone ridge volume. **Fig. 3:** CBCT showing incisive foramen and its association with affected tooth. **Fig. 4:** Further CBCT view showing adjacent root positions.



**Fig. 5:** Implant planning showing engagement of apical bone. **Fig. 6:** Implant apical portion in bone without engagement of nasal floor. **Fig. 7:** Significant bone volume between implant and adjacent roots.

Presurgical antibiotic prophylaxis with a five-day course of amoxicillin 250mg given three times daily was prescribed. Under local anaesthesia, minimally traumatic flapless tooth extraction was performed (Fig. 8) using a 15c scalpel blade (Swann Morton), periostomes (Hu Friedy Group) and extraction forceps (Hu Friedy Group), ensuring minimal plastic flexing of the intact labial and lingual plates of intact bone. Immediately post extraction the socket and apical defect were debrided of granulation tissue using both Lucus

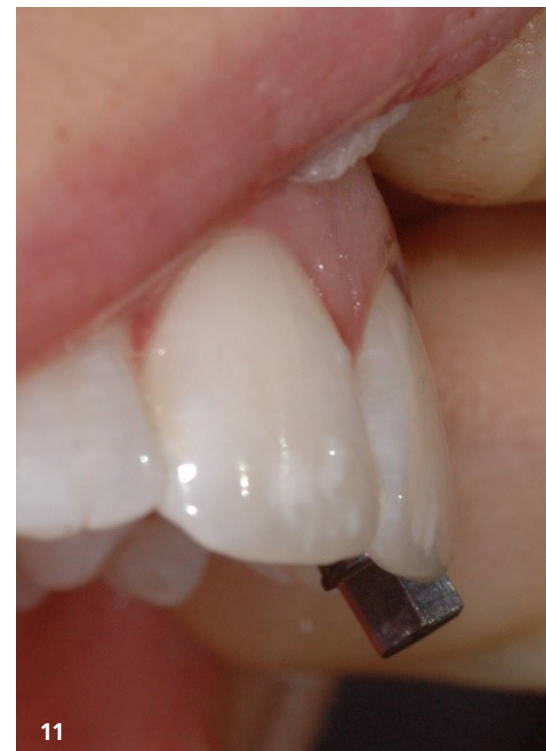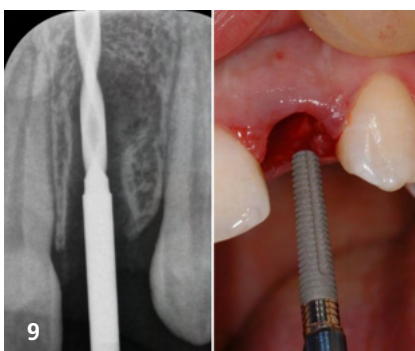
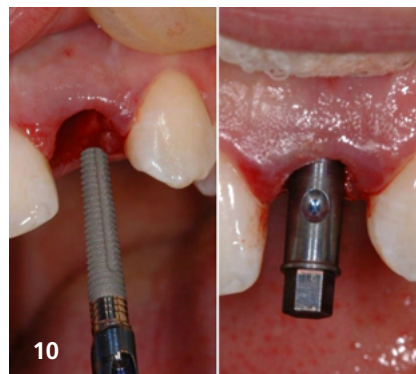
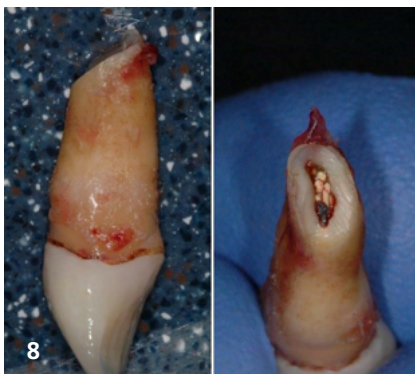curettes (Hu-Friedy Group), degranulation burs (EthOss EK Strauss Degranulation Bur Kit, EthOss), and copious 0.9% sterile saline irrigation.

After completion of degranulation, the socket and apical bony defect were evaluated and both the labial and palatal bony plates were found to be intact.

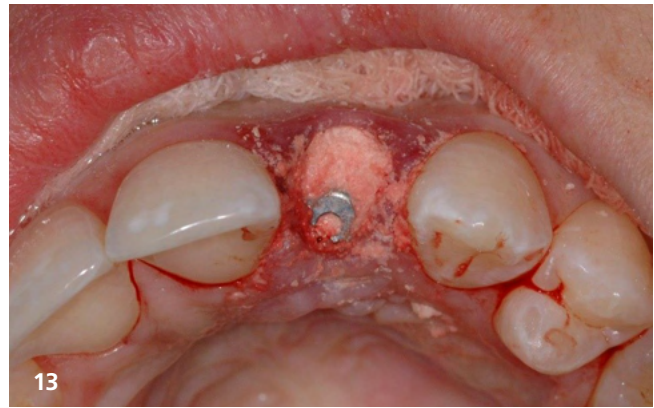
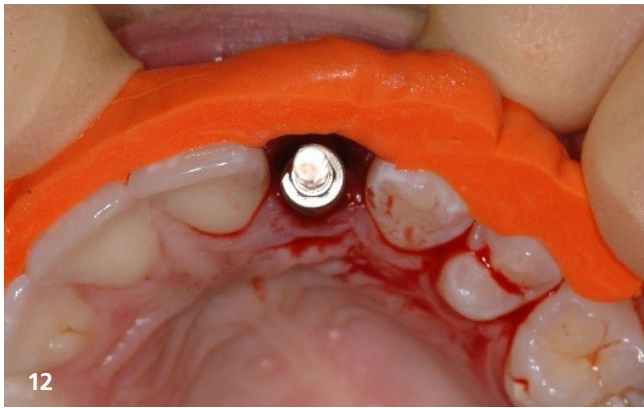
An osteotomy was created using a sharp lance drill followed by a 2mm twist drill, and then tapered twist drills to 19mm depth (Southern Implants; Fig. 9), leading to an undersized osteotomy within the

original bony envelope for a Southern Tapered MSC External Hex 18mmx4mm implant (Southern Implants), a novel implant design with a machined coronal portion and an internal angle correction (Figs. 10 & 11). This implant combines a relatively narrow profile with length suitable to help achieve high primary stability for immediate tooth replacement therapy in the maxilla and was chosen due to the tall, narrow ridge form.

The implant was placed into the ideal position at 60Ncm, with the aid of a sur-



**Fig. 8:** Extracted UL2. The socket was then thoroughly degranulated and cleansed of all soft tissue remains using EthOss degranulation burs (Swallow Dental), curettes and copious irrigation with saline. **Fig. 9:** Osteotomy created using a sharp drill followed by a 2mm twist drill. **Fig. 10:** The MSC portion of the implant and the correct rotational axis after placement. **Fig. 11:** Southern Tapered MSC External Hex 18mm x 4mm implant placed to correct 3D position.



**Fig. 12:** Implant placed at 60Ncm, with the aid of a surgical guide. **Fig. 13:** EthOss Bone Grafting material placed into the site around a 4 mm healing abutment.

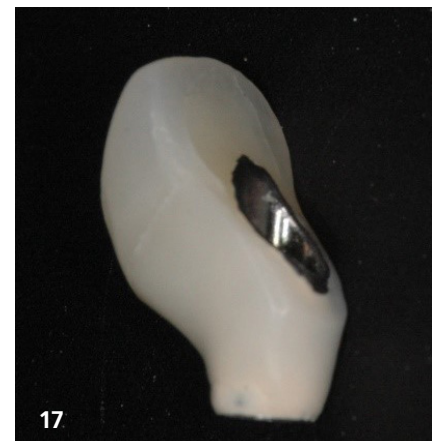
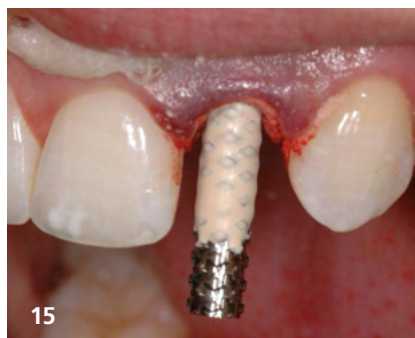gical guide manufactured from O-Bite silicone bite registration material, (AHP Medicals; Fig. 12). A healing abutment was placed prior to site augmentation with a resorbable synthetic bone grafting material (EthOss; EthOss), a novel biphasic bone substitute consisting of  $\beta$ -TCP (65 %) and calcium sulphate (CS, 35 %). 0.5 cc of the material was hydrated with 0.9 % sterile saline, mixed and partially dried, according to manufacturer's instructions and placed directly over the exposed implant threads within the circumferential jumping gap (Fig. 13). Gentle pressure for 3–5 minutes with a piece of sterile low-lint gauze al-

lowed time for the material to 'set'. The healing abutment was then removed and replaced with a titanium temporary engaging cylinder to 20Ncm (Southern Implants; Fig. 14), cosmetically masked with composite opaquer (BISCO; Fig. 15). The composite shell provisional crown (Fig. 16) was positioned and attached to the titanium cylinder using flowable, light curing composite resin (G-aenial Anterior, GC Europe), followed by its removal (Fig. 17), modification and finishing at chairside using polishing burs (Kenda C.G.I. One, Coltène/Whaledent) and disks (Super Snap, SHOFU Dental). Meticulous occlusal anal-

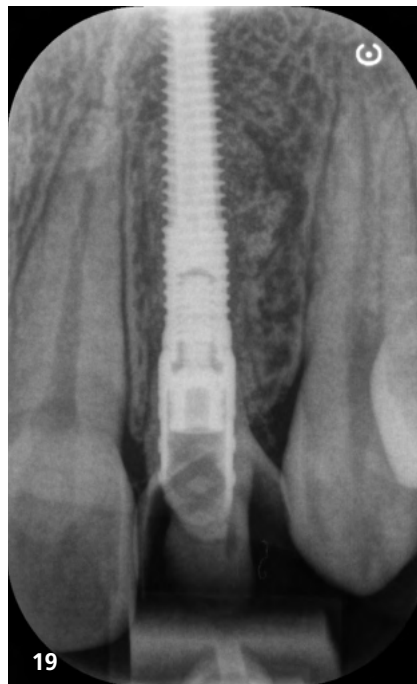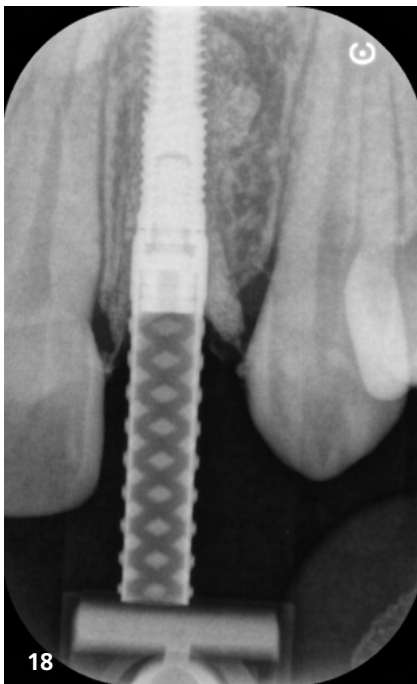
ysis ensured the crown was not in occlusion in either centric or excursive occlusal positions (Figs. 18–20).

At review 14 days postsurgery, the restoration was assessed for mobility, the occlusion reassessed, and the oral hygiene status assessed and modified. Excellent initial healing was observed (Figs. 21 & 22).

At three-month review, the provisional crown had assimilated well into the oral scheme and the patient was masticating her normal diet with normal function. The patient was thus scheduled for the impression stage.



**Fig. 14:** Healing abutment removed and replaced with a titanium temporary engaging cylinder to 20Ncm. **Fig. 15:** Titanium temporary engaging cylinder to 20Ncm cosmetically masked with composite opaquer. **Fig. 16:** The composite shell provisional crown. **Fig. 17:** Composite shell provisional crown positioned and attached to the titanium cylinder using flowable, light cured composite resin.



**Fig. 18:** Immediate post-placement radiograph showing EthOss in both apical defect and jump gap.

**Fig. 19:** Radiograph after provisional crown fitting showing accurate fit.

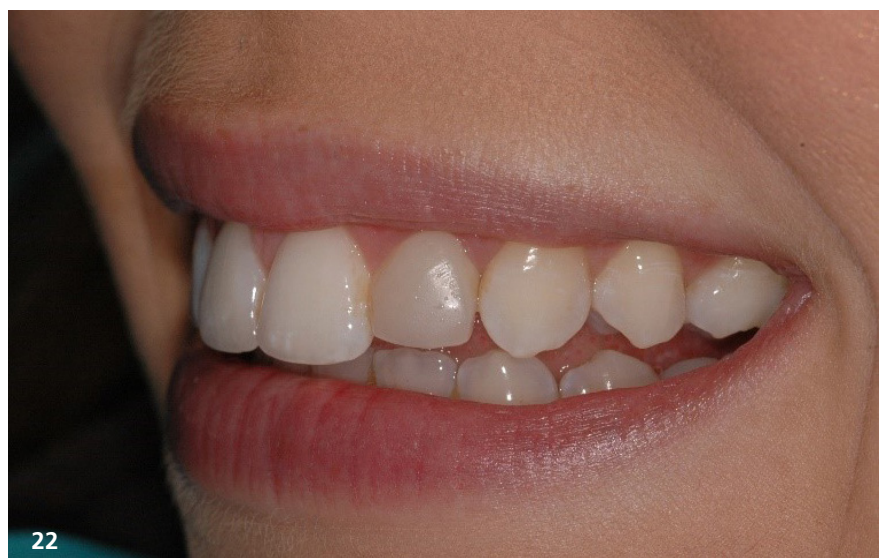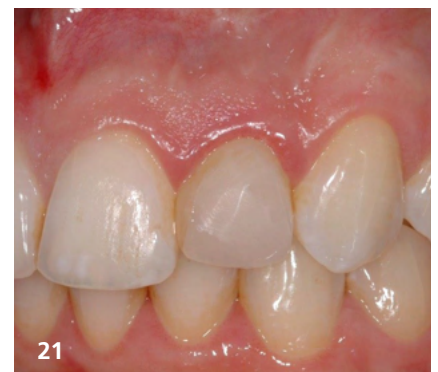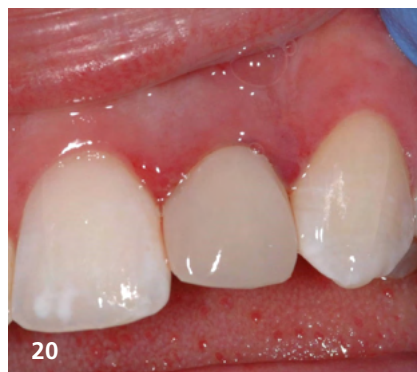ination compared to a moderately rough implant surface.

The bioactive  $\beta$ -TCP and CS combination produces a grafting substrate that self-hardens, with the CS having a barrier function, preventing soft-tissue ingress during the early phases of bone-regeneration. The CS resorbs in a three-to-six-week window dependent of individual patient physiology, and as it resorbs, it creates interlinked porosities within the  $\beta$ -TCP scaffold for angiogenesis.

The  $\beta$ -TCP scaffold resorbs over a 6–12-month period due to a combination of phagocytosis, hydrolysis and bony enzymic action. As both the CS and  $\beta$ -TCP are fully resorbable bone augmentation materials, host bone is regenerated without the continued presence of residual graft particles.

This case study shows amendments from the original published protocol<sup>2</sup>

A digital impression was taken using a Medentika scan body (Medentika) and a Trios intra-oral scanner (3shape). A custom screw-retained zirconia crown, with titanium lab-bonded abutment was delivered to the mouth and fitted to 35 Ncm. Silver plug (Silveraid), and G-aenial composite (GC Europe), were used to occlude the palatal screw channel. A post fit radiograph showed a well fitting restoration and complete socket healing with host bone (Figs. 23–27).

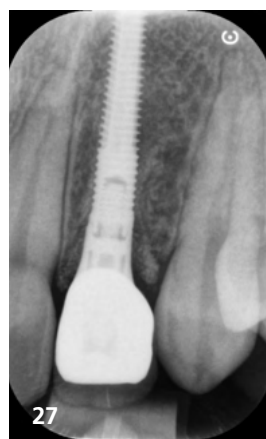
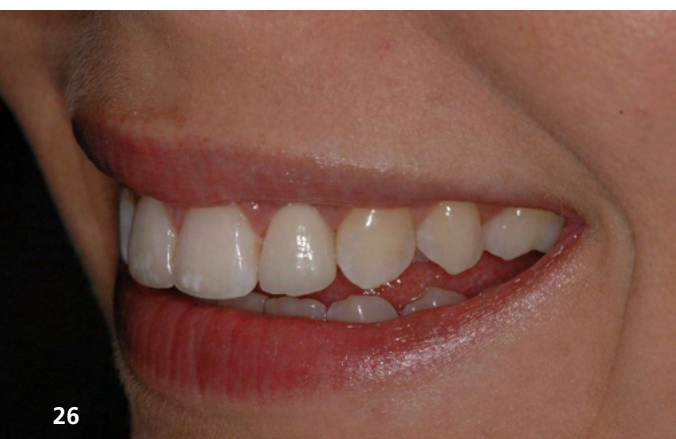
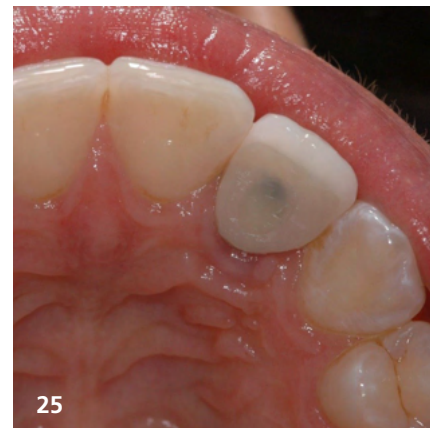
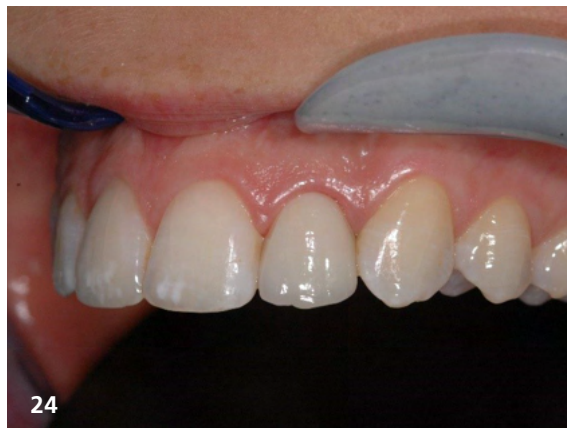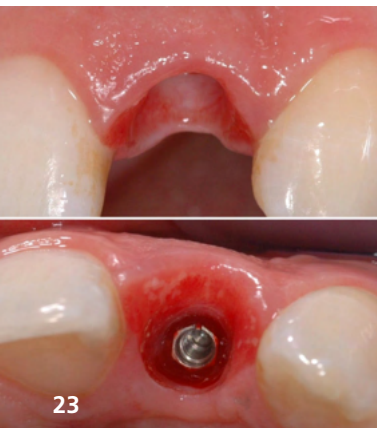## Discussion

This case provides an example of the use of a novel site-specific implant with a bioactive alloplastic  $\beta$ -TCP and CS material, in an immediate tooth replacement protocol.

The premise of the novel implant design features an internal angle correction of 12 degrees, allowing optimised screw channel position palatally, whilst engaging favourable mid-ridge bone. In addition, the machined coronal surface is purported to be more resistant to peri-implant disease, due to a reduced propensity to microbial and microbial product contam-

**Fig. 20:** Immediate postoperative image. **Figs. 21 & 22:** One-week postoperative situation.



**Fig. 23:** Three months postoperative image showing preservation of anatomical features (bleeding due to hemidesmosomal attachment).

**Fig. 24:** Final restoration—buccal view. **Fig. 25:** Final restoration—palatal view showing screw access channel. **Fig. 26:** Final restoration. **Fig. 27:** Final radiograph showing full bony healing and crown emergence.

where these materials are used in delayed immediate procedures. Here an immediate tooth replacement protocol is used with simultaneous grafting for enhanced preservation of host hard tissues, along with up-regulated host-regeneration.<sup>1</sup>

The  $\beta$ -TCP graft constituent shows both osteoconductive, but also, osteo-inductive potential, which enhances host bone regeneration during the postsurgical healing period. The self-hardening nature of the CS means graft stability during the crucial early contact with the host periosteum. The internal angle correction of the implant allowed mid-ridge positioning and thus, a circumferential jumping gap for increased graft volume within the original bony envelope, facilitating ideal palatal screw channel emergence, without the use of ASCs, with their potential pitfalls, or the use of a cement-retained solution with its well-documented issues.

For further reading regarding the science specific to bioactive calcium phosphates and their clinical applications, the

readers may refer to papers published in previous issues of the *EDI Journal* and other international journals.<sup>1-4, 12-16</sup>

### Conclusion

To conclude, the use of this novel site-specific implant design in conjunction with immediate tooth replacement therapy and the use of a fully resorbable bioactive alloplastic graft material may have resulted in a synergistic result for this case, with a very pleasing outcome for this patient. It is vitally important that clinicians are well versed in the surgical procedures they utilise, and fully understand the handling characteristics and other specific properties of the grafting protocols they elect to use, so that they can optimise the complex biological and osteo-immune mechanisms of host bone regeneration for each individual implant-based surgical procedure, and improve both predictability and long-term success of their implant dentistry practice.

Author details



### Contact address

**Dr Mark Worthing**  
Tupsley Dental Practice  
60 Aylestone Hill  
Hereford, HR1 1HX, UK  
[www.tupsleydentalpractice.co.uk](http://www.tupsleydentalpractice.co.uk)